

Eye complications after head trauma in children

Ophthalmological complications

Kiril Slaveykov¹, Kalina Trifonova², Stefan Valkanov³, Valentin Stoyanov⁴

¹Department of General Medicine, ²Department of Ophthalmology, ³Department of Neurosurgery, ⁴Department of Otorhinolaryngology, Trakia University, Stara Zagora, Bulgaria

Abstract

Aim: In this study, we aimed to assess the importance and frequency of ocular complications of head trauma. **Material and Method:** This research paper presents a cross-sectional study of 77 children with head injury. The study was carried out at the University Hospital "Prof. Dr. Stoian Kirkovich", Stara Zagora, Bulgaria, Department of Neurosurgery. Participants were recruited consecutively into the study during the period from January 2016 to January 2018 and underwent a thorough ophthalmic and neurosurgical examination. The analysis included age, sex, the cause of head injury, and ocular findings. **Results:** The leading causes of head injury were domestic accidents (45.5%) and fall in playgrounds (33.8%). Ocular findings were observed in 56 (72.72%) cases of head injury. Most common complications were ocular adnexa damage (29.9%) and anterior segment damage (27.3%). Severe damage including orbital fractures was found in 1 patient. There is no statistically significant difference in gender, although males were more prone to sports activity related accidents. The main complaint of males was the pain in the ocular area, while females considered the swelling a primary concern. Age also plays a factor, with the highest frequency of incidences between 10 and 15 years. **Discussion:** Additional problems which require attention are head trauma due to child abuse, overprotective parents exacerbating the children's complaints and the need for emergency evaluation of visually asymptomatic patients with orbital fractures.

Keywords

Head Trauma; Children; Ophthalmological Complications; Bulgaria

DOI: 10.4328/ACAM.6096 Received: 01.12.2018 Accepted: 21.01.2019 Published Online: 22.01.2019 Printed: 01.11.2019 Ann Clin Anal Med 2019;10(6): 671-5
Corresponding Author: Kiril Slaveykov, Department of General Medicine, Trakia University, Stara Zagora, Bulgaria.
T.: +359886712078 E-Mail: kirilslaveykov@gmail.com

Introduction

Sources show that the leading causes of head injury include traffic accidents, falls, and physical assault [2]. Less frequently the cause can be accidents at home, work, outdoors, or while playing sports [17, 22]. There is a considerable variation, however, as road accidents are only 24% in Scotland compared to 90% in Taiwan. Similarly, assaults to males range from 1% in France to 45% in Johannesburg [9]. Similar studies carried out in Kenya show the leading cause of head trauma to be traffic accidents (44.9%) and assaults (42.2%), followed by falling from a height (7.5%) [15]. In Germany, the predominant cause of traumatic head injury are falls, with 52.5% of all cases, while 26.3% were due to road accidents [19]; in Pakistan, traffic accident cause 52.4% and fights cause 38.5% of head trauma [24]. The visual system is frequently involved in head trauma due to the proximity of the eye to the head as well as due to the neural connections between the eye and the brain [15].

Head injuries cause the hospitalization of 200–300 individuals per 100 000 per year worldwide and about 25% of these are associated with ocular and visual defects [1]. There are relatively few studies focusing on eye complications after traumatic brain injury in children. Shokunbi et al. found that they occurred in 28% of all head traumas. Neuro-ophthalmological lesions made up one-third of these complications, mostly involving the optic nerve, these were associated with other focal neurological signs more frequently than non-neural ocular complications. Lesions of the posterior visual pathways were rare but tended to be permanent [21]. Head trauma is a frequent cause of childhood morbidity and mortality. There are statistically significant differences showing that children aged from zero to 12 years are at risk for ocular complications more frequently than older children [5]. Kraus et al. also report the head injury is not uniform across all ages. Children between ages 1-5 years have similar incidence, whereas after that age head injury rates increase for males and decrease for females [13].

The frequency of different cases differs between children and adults, as well as between countries. In North America, Europe, Australia, and New Zealand, falls are the leading cause of injury among children aged less than 5 years and motor-vehicle crashes - among youths aged 15 years and older [23]. In China, the three leading causes responsible for child head injuries are falls (69.57%), blunt force trauma (14.23%) or road traffic collisions (11.01%). They are most likely to happen at home (44.98%), public places (19.65%) or on roads/streets (15.81%). Recreational activities (77.88%), driving (7.32%) and sports (5.72%) were the three major activities causing the injuries [11]. Research based on head trauma in children younger than 2 years of age also cites falls as a major factor with 24% of injuries presumed inflicted, and an additional 32% were suspicious for abuse, neglect, or social/family problems [7]. Traffic accidents have become less common, even though they still lead to severe damage and complications, while recreation and/or sports-related trauma have become more frequent, but are related to less severe injuries [12].

The prompt diagnosis of ocular symptoms and signs and their differentiation can be of value in the early and correct diagnosis of head trauma, thus ensuring effective treatment [5]. This

is essential to maximize the overall rehabilitation potential [20]. In this study, we aimed to assess the importance and frequency of ocular complications of head trauma.

Material and Method

A cross-sectional study of 77 patients admitted with head trauma at University Hospital, Stara Zagora, Bulgaria, was carried out for a 2-year period (January 2016 – January 2018). Patients were recruited consecutively based on history, neurological findings, and the following criteria:

- Age of patient <18 years
- Recent head trauma < 1 week

A full ophthalmic examination was carried out within the first week of admission into the hospital. Visual acuity was assessed using Monoyer chart at 6 meters. In patients younger than 2 years, testing was done using preferential looking techniques with Teller acuity cards. The analysis was done using the Statistical Package for the Social Sciences (SPSS) version 16.0 software. Patients were managed according to their respective diagnoses by the neurosurgical and ophthalmologic units.

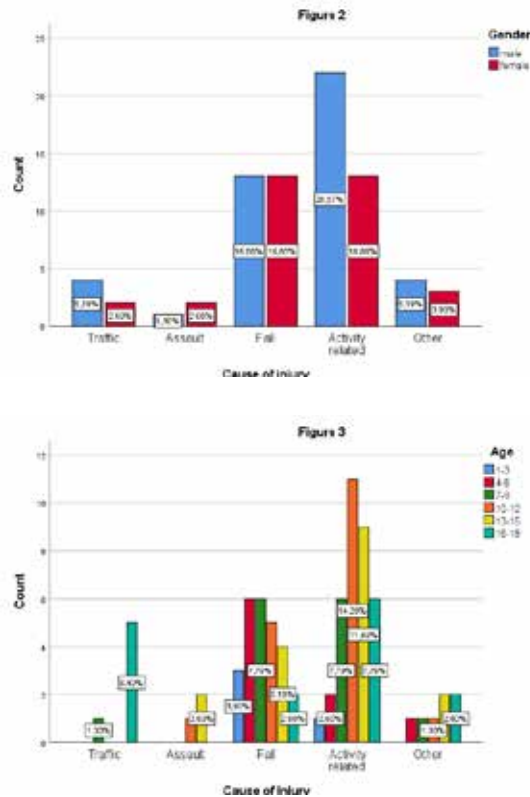
Results

Out of the 77 patients recruited for the study, visual and ocular complications occurred in 56 (72.72%) (Figure 1). There were 44 male (57.1%) and 33 female (42.9%) participants, giving a 1, 3:1 male to female ratio. The ages varied from 1 to 18 years, with the youngest patient being 1 year and 1 month old and the eldest 17 years and 7 months. The mean age of the patients was 10 years and 7 months. The majority of the patients were in the 10-15 years range (45.45%).

Four cases were associated with damage outside of the head, including injury to the abdomen, chest or extremities. Complications from the visual system were divided into five groups, depending on the damaged parts: ocular adnexa, anterior segment, posterior segment, neuro-ophthalmic, orbital fractures. In 20% of the cases, the reported damage included more than one complication. From the 56 patients with eye complications, solitary injuries to the right eye occurred in 24 patients, in the left eye in 18 patients, in both eyes in 14.

Traffic accidents were responsible for only 7.8% of all head injuries, with the main participants being usually male and in the 16-18 years spectrum. In all cases with a patient driver (66.66%), they reported not following traffic regulations as a cause for the accident. The remaining two patients were a passenger and a pedestrian. Assault caused 3.9% of head injuries, with all cases being consequences of school fights. Falling was reported as the second most prominent reason for head injury (38.8%), with most patients under the age of 9 injuring themselves on the playground. The leading cause of head trauma was activity-related injury (sports and/or recreation) (45.5%) which included playground accidents for younger children, sports accidents for children in school and domestic accidents (falling items, hitting head on corners, stumbling etc.). These leading causes are similar in frequency and type to those found in the literature [7, 11, 23]. There were no statistically significant differences (Pearson $\chi^2 > 0, 05$) between the genders, although male patients showed a tendency for injury during physical activity more than females. Most accidents occurred in

the 10-15 years range. (Figure 2, Figure 3) which corresponds to Cantani et al. [5]. There was only one case of orbital fracture (1.3%), caused by an assault on a female in the 10-12 years group, and one case (1.3%) of neuro-ophthalmic complications (papilloedema) in a female in the 16-18 years group caused by the pedestrian traffic accident. The most common complications were damage to the ocular adnexa (29.9%) (mainly ecchymosis and lid lacerations), and anterior segment (27.3%) (mainly corneal epithelial defects). The main causes for adnexal (47.8%) and anterior segment (42.8%) damage is activity related injury. Posterior segment complications are rarer (13.0%) and usually follow fall injury (40.0%). (Table 1)



tions), and anterior segment (27.3%) (mainly corneal epithelial defects). The main causes for adnexal (47.8%) and anterior segment (42.8%) damage is activity related injury. Posterior segment complications are rarer (13.0%) and usually follow fall injury (40.0%). (Table 1)

There was a statistically significant relationship between eye complications and cause of injury. Ocular adnexa complications were observed most often during physical activities, whereas anterior segment damage occurred after falls and sports injuries, and posterior segment occurred after falls.

During the first examination after admittance, 41 out of 77 children (53.25%) had decreased visual acuity. During the second week of examination, only 3 cases still had reduced vision. This corresponded to the severity of the diagnosed complications: more severe trauma to the posterior segment, neuro-ophthalmic damage or orbital fractures were connected with worse visual results (Table 3). During the sixth month follow up, only 1 case had 0,9 vision, with the rest being 1,0. There was a statistically significant relationship between eye complications and visual acuity ($p<0,05$).

The pain was the most common complaint (50.64%) and it was mainly connected to damage to ocular adnexa. Despite this, there were 8 cases (10.39.5%) where pain in the eye area was the major symptom, but with no ocular complications. There was no statistically significant relationship between gender and complaints, though there was a tendency for males to complain more about pain and females more about swelling (Figure 4)

Discussion

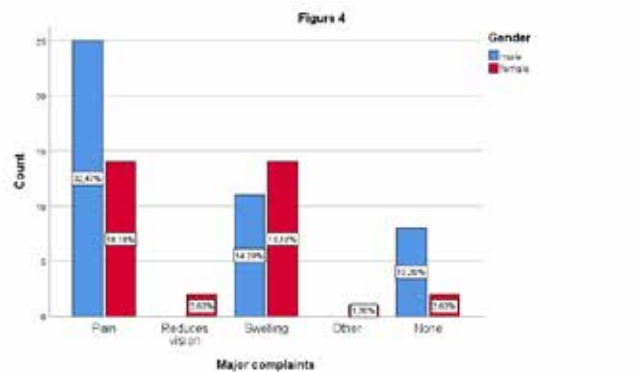
Head trauma due to a child abuse should not be forgotten as a possible cause of injury [6]. Our study does not include such cases, but due to the age of some of the children and the lan-

Table 1. Eye complication

Ocular Adnexae		Posterior segment	Neuro-ophthalmic	Orbital fracture	None			Total	
Anterior segment									
Cause of injury	Traffic	Count	2	2	0	1	0	1	6
		% within Eye complication	8,7%	9,5%	0,0%	100,0%	0,0%	4,8%	7,8%
		% of Total	2,6%	2,6%	0,0%	1,3%	0,0%	1,3%	7,8%
	Assault	Count	0	0	1	0	1	1	3
		% within Eye complication	0,0%	0,0%	10,0%	0,0%	100,0%	4,8%	3,9%
		% of Total	0,0%	0,0%	1,3%	0,0%	1,3%	1,3%	3,9%
	Fall	Count	7	9	4	0	0	6	26
		% within Eye complication	30,4%	42,9%	40,0%	0,0%	0,0%	28,6%	33,8%
		% of Total	9,1%	11,7%	5,2%	0,0%	0,0%	7,8%	33,8%
	Activity related	Count	11	9	3	0	0	12	35
		% within Eye complication	47,8%	42,9%	30,0%	0,0%	0,0%	57,1%	45,5%
		% of Total	14,3%	11,7%	3,9%	0,0%	0,0%	15,6%	45,5%
	Other	Count	3	1	2	0	0	1	7
		% within Eye complication	13,0%	4,8%	20,0%	0,0%	0,0%	4,8%	9,1%
		% of Total	3,9%	1,3%	2,6%	0,0%	0,0%	1,3%	9,1%
Total	Count	23	21	10	1	1	21	77	
% within Eye complication	100,0%	100,0%	100,0%	100,0%	100,0%	100,0%	100,0%		
% of Total	29,9%	27,3%	13,0%	1,3%	1,3%	27,3%	100,0%		

Table 2. Chi-Square Tests			
	Value	df	Asymptotic Significance (2-sided)
Pearson Chi-Square	45,001 ^a	20	,001
Likelihood Ratio	22,118	20	,334
N of Valid Cases	77		

Table 3. Visual acuity							
		1,0 0,6 - 0,9	Log mar 4			Total	
			0,1 - 0,5	<0,1			
Eye complication	Ocular Adnexae	Count	18	4	1	0	23
		% within Log mar 4	50,0%	12,9%	11,1%	0,0%	29,9%
		% of Total	23,4%	5,2%	1,3%	0,0%	29,9%
	Anterior Seg- ment	Count	6	15	0	0	21
		% within Log mar 4	16,7%	48,4%	0,0%	0,0%	27,3%
		% of Total	7,8%	19,5%	0,0%	0,0%	27,3%
	Pos- terior Seg- ment	Count	5	2	3	0	10
		% within Log mar 4	13,9%	6,5%	33,3%	0,0%	13,0%
		% of Total	6,5%	2,6%	3,9%	0,0%	13,0%
	Neuro- ophthal- mic	Count	0	1	0	0	1
		% within Log mar 4	0,0%	3,2%	0,0%	0,0%	1,3%
		% of Total	0,0%	1,3%	0,0%	0,0%	1,3%
	Orbital Frac- tures	Count	0	0	0	1	1
		% within Log mar 4	0,0%	0,0%	0,0%	100,0%	1,3%
		% of Total	0,0%	0,0%	0,0%	1,3%	1,3%
None	Count	7	9	5	0	21	
	% within Log mar 4	19,4%	29,0%	55,6%	0,0%	27,3%	
	% of Total	9,1%	11,7%	6,5%	0,0%	27,3%	
Total	Count	36	31	9	1	77	
% within Log mar 4		100,0%	100,0%	100,0%	100,0%		
% of Total		46,8%	40,3%	11,7%	1,3%	100,0%	



guage barrier with children from minorities, the history is taken from the parents and cannot be verified. If anything observed suggests domestic violence, social services need to be involved immediately [10]. In lethal cases, histopathologic analysis of optic nerve sheath and intraocular hemorrhages can help in distinguishing between traumatic and non-traumatic causes of death in infants [4]. Identifying cherry hemorrhages may also aid abusive head trauma diagnosis. Survivor abusive head trauma pathology demonstrates unique, irreversible macular and

optic nerve damage [3]. Another problem encountered during the study was overprotective and worried parents. Even though only one case was outside of the criteria for a mild brain injury [8], with a Glasgow Coma Scale score of <13, CT was performed on all them, due to the fact that parents usually exaggerating the complaints of the child. The factor most commonly speculated with was the time of unconsciousness, with parents quoting several minutes of unconsciousness, while the patients themselves were unsure if they even lost consciousness. A head injury often requires additional examinations, but due to the risks of radiation-induced malignancy from computed tomography (CT) imaging, it is important to prevent excessive exposition especially in children. Prof. Nathan Kuppermann et al. present several criteria that can be used to choose whether CT is required or not [14]. The topic is further discussed by Patricia Parkin and Jonathon Maguire suggesting additional examinations should be avoided whenever possible [18]. Another topic which needs to be addressed is whether visually asymptomatic patients with orbital fractures require emergency evaluation from an ophthalmologist. The research by Mellem et al. found that asymptomatic patients were unlikely to have severe ocular injury in the setting of an orbital fracture. In addition, visual acuity did not accurately predict the presence of a severe ocular injury [16]. Our findings agree with their statement as 70% of the asymptomatic patients had no neurological findings and 1.0 vision, with the other 30% also having no neurological findings and slightly reduced vision (>0.6). As the leading causes for injury among children were falling and playground accidents, more thorough supervision from their parents could prevent most of them.

Conclusion
The leading causes of head trauma in children were falling and sports/recreational activity-related injury. There is no statistically significant difference in gender, although males were more prone to sports activity related accidents. Age also plays a role with the highest frequency between 10 and 15 years. The most commonly affected parts of the eye were the adnexa and anterior segment, comprising more than 50% of all eye complications. The main complaint for males was pain in the ocular area, while females considered the swelling a primary concern. Light injuries like bruises and lacerations to the eyelids and minor epithelial defect did not have future consequences. In most cases, they require no or minimal treatment. Moderate conditions like commotion retinae, papilloedema and retinal hemorrhages require thorough follow up and adequate treatment to prevent permanent visual loss. Severe damages with neuro-ophthalmological complications like ptosis and strabismus require long term follow-ups and in cases with no improvement - surgical intervention.

Scientific Responsibility Statement
The authors declare that they are responsible for the article's scientific content including study design, data collection, analysis and interpretation, writing, some of the main line, or all of the preparation and scientific review of the contents and ap-

proval of the final version of the article.

Animal and human rights statement

All procedures performed in this study were in accordance with the ethical standards of the institutional and/or national research committee and with the 1964 Helsinki declaration and its later amendments or comparable ethical standards. No animal or human studies were carried out by the authors for this article.

Funding: None

Conflict of interest

None of the authors received any type of financial support that could be considered potential conflict of interest regarding the manuscript or its submission.

References

1. Baker RS, Epstein AD. Ocular motor abnormalities from head trauma. Survey Ophthalmol. 1991; 35(4): 245–67.
2. Brazinova A, Rehorcikova V, Taylor MS, Buckova V, Majdan M, Psota M, et al. Epidemiology of traumatic brain injury in Europe: a living systematic review. Journal of Neurotrauma. 2016. DOI:10.1089/neu.2015.4126
3. Breazzano MP, Unkrich KH, Barker-Griffith AE. Clinicopathological findings in abusive head trauma: analysis of 110 infant autopsy eyes. American journal of ophthalmology. 2014; 158(6): 1146–54.
4. Budenz DL, Farber MG, Mirchandani HG, Park H, Rorke LB. Ocular and optic nerve hemorrhages in abused infants with intracranial injuries. Ophthalmology. 1994;101(3): 559–65
5. Cantani A, Bamonte G. Epidemiology of ocular complications of childhood head trauma. Pediatr Emerg Care. 1990; 6(4): 271–4.
6. Christian CW, Block R. Abusive head trauma in infants and children. Pediatrics. 2009; 123(5): 1409–11.
7. Duhaime AC, Alario AJ, Lewander WJ, Schut L, Sutton LN, Seidl TS, et al. Head injury in very young children: mechanisms, injury types, and ophthalmologic findings in 100 hospitalized patients younger than 2 years of age. Pediatrics. 1992; 90(2): 179–85.
8. Head J. Definition of mild traumatic brain injury. J Head Trauma Rehabil. 1993; 8(3): 86–7.
9. Jennett B. Epidemiology of head injury. J Neurol Neurosurg Psychiatry. 1996; 60(4): 362–9.
10. Jenny C, Hymel KP, Ritzen A, Reinert SE, Hay TC. Analysis of missed cases of abusive head trauma. Jama. 1999; 281(7): 621–6.
11. Ji C, Duan L, Er Y, Ye P, Wang Y, Deng X, et al. Study on child head-injuries through data derived from the National Injury Surveillance System of China. 2014. Zhonghua liu xing bing xue za zhi= Zhonghua liuxingbingxue zazhi. 2016;37(4): 527–30.
12. Kraus JESS F. Epidemiological features of brain injury in children: Occurrence, children at risk, causes and manner of injury, severity, and outcomes. Traumatic head injury in children. In Broman, S.H. & Michel, M.E. (editors.) New York: Oxford University Press; 1995. p.22–39.
13. Kraus J. F, Fife D., Ramstein K, Conroy C, Cox P. The relationship of family income to the incidence, external causes, and outcomes of serious brain injury, San Diego County, California. American Journal of Public Health. 1986; 76(11): 1345–47.
14. Kuppermann N, Holmes JF, Dayan PS, Hoyle JD, Atabaki SM, Holubkov R, et al. Identification of children at very low risk of clinically-important brain injuries after head trauma: a prospective cohort study. The Lancet. 2009; 374(9696): 1160–70.
15. Masila F, Kiboi J, Marco S, Njuguna M. Ocular findings in patients with head injury. JOECSA. 2015; 18(2): 83–9.
16. Mellema PA, Dewan MA, Lee MS, Smith SD, Harrison AR. Incidence of ocular injury in visually asymptomatic orbital fractures. Ophthal Plast Reconstr Surg. 2009;25(4): 306–8.
17. Nguyen R, Fiest KM, McChesney J, Kwon CS, Jette N, Frolkis AD, et al. The international incidence of traumatic brain injury: a systematic review and meta-analysis. Canadian journal of neurological sciences. 2016; 43(6): 774–85.
18. Parkin PC, Maguire JL. Clinically important head injuries after head trauma in children. The Lancet. 2009; 374(9696): 1127–9.
19. Rickels E, von Wild K, Wenzlaff P. Head injury in Germany: a population-based prospective study on epidemiology, causes, treatment and outcome of all degrees of head-injury severity in two distinct areas. Brain injury. 2010; 24(12): 1491–504.
20. Sabates NR, Gonce MA, Farris BK. Neuroophthalmological findings in closed head trauma. J. Clin. Neuro-Ophthalmol. 1991; 11: 273–7.
21. Shokunbi T, Agbeja A. Ocular complications of head injury in children. Childs

Nerv Syst. 1991; 7(3): 147–9.

22. Stratton MC, Gregory RJ. After traumatic brain injury: a discussion of consequences. Brain Inj. 1994; 8(7): 631–45

23. Thurman DJ. The epidemiology of traumatic brain injury in children and youths: a review of research since 1990. Journal of child neurology. 2016; 31(1): 20–7.

24. Zaidi SS, Fatima A. Traumatic brain injury-a leading cause of death in Pakistan. A prospective study. Journal of the Neurological Sciences. 2017; 381:753.

How to cite this article:

Slaveykov K, Trifonova K, Valkanov S, Stoyanov V. Eye complications after head trauma in children. Ann Clin Anal Med 2019;10(6): 671–5.